

Management of Barrett's oesophagus

Jayan Mannath and Krish Rangunath*

Address: Nottingham Digestive Diseases Centre and Biomedical Research Unit, Queen's Medical Centre Campus, Derby Road, Nottingham University Hospitals NHS Trust, Nottingham, NG7 2UH, UK

*Corresponding author: Krish Rangunath (k.rangunath@nottingham.ac.uk)

F1000 Medicine Reports 2009, **1**:7 (doi: 10.3410/MI-7)

The electronic version of this article is the complete one and can be found at: <http://F1000.com/Reports/Medicine/content/1/7>

Abstract

Barrett's oesophagus, which is thought to be a consequence of gastro-oesophageal reflux disease (GORD), is a well-recognized precursor of oesophageal adenocarcinoma. Medical therapies and anti-reflux surgeries for GORD have shown conflicting results regarding the progression of Barrett's metaplasia to neoplasia. After high-grade dysplasia or intramucosal cancer is identified, it has been standard practice to conduct an oesophagectomy, despite this having an associated risk of morbidity and mortality. In recent years however, endoscopic therapy has become a viable alternative to oesophagectomy in treating early neoplasia.

Introduction and context

Barrett's oesophagus (BO) is characterized by replacing the distal oesophageal squamous mucosa with columnar epithelium containing specialized intestinal metaplasia (IM). The metaplastic epithelium accumulates genetic changes over a period of time and can progress to dysplasia and cancer. These patients carry a cancer risk that is 30 to 125 times more than that of an age-matched population [1]. Screening for BO remains controversial, but regular surveillance is a standard practice once IM is identified. Guidelines set out by The American College of Gastroenterology, as well as those of several other national gastrointestinal societies, suggest that quadrantic biopsies should be conducted every 2 cm of BO during surveillance. However, with recent advanced imaging techniques such as autofluorescence and narrow band imaging, biopsies can be targeted with good yield to detect early neoplasia [2].

Medical management

The main aim of treatment in BO is to control reflux symptoms and prevent the development of dysplasia and cancer. Medical therapies are mainly directed toward controlling gastro-oesophageal reflux disease. H₂-receptor antagonists have shown benefits in controlling symptoms of BO but have not shown regression in the

length of metaplastic epithelium [3]. Similarly, proton-pump inhibitors (PPIs) are useful in treating oesophagitis associated with BO, but there is no consistent evidence to suggest significant regression of disease or benefits in preventing the development of neoplasia. Control of reflux symptoms by PPIs does not necessarily equate with complete inhibition of acid reflux and some patients can have bile reflux, which is known to influence the development and persistence of metaplastic epithelium. An increase in squamous islands is noted after PPI use, but studies show that IM is often present underneath those islands [4].

Chemoprevention measures using non-steroidal anti-inflammatory drugs and aspirin in BO have shown some benefits in preventing the development of neoplasia [5]. However, results from the recent Chemoprevention for Barrett's Esophagus Trial (CBET) were disappointing with regard to the use of celecoxib [6]. Ongoing trials like the Aspirin Esomeprazole Chemoprevention Trial (AspECT) will throw light on to the role of aspirin in preventing Barrett's associated cancer of the oesophagus.

Surgical management

Laparoscopic anti-reflux surgeries like fundoplication have the benefit of controlling acid and bile reflux better

than medical therapy, however, the ability to prevent the development of cancer in BO is conflicting. Some studies have shown a progression to cancer in spite of surgery and there is no consistent evidence to suggest the regression of Barrett's mucosa following surgery [7]. Once high-grade dysplasia is identified, oesophagectomy has been the standard practice, however newer endotherapeutic techniques are now capable of treating dysplasia and early cancer, thereby avoiding major surgery.

Endoscopic ablation techniques

Argon plasma coagulation (APC) uses an ionized electrically conducting argon beam that delivers a high local temperature of 130°C leading to desiccation of tissue to a maximum depth of 3 to 4 mm, which is ideal to destroy the metaplastic epithelium [8]. Many studies involving APC have shown benefits of eradication of Barrett's mucosa and early neoplasia with restoration of squamous epithelium [8,9]. Multipolar electrocoagulation using a gold probe has been shown to be equally effective, with up to 70% of patients showing a complete reversal of Barrett's epithelium [10]. Unlike these techniques, photodynamic therapy (PDT) involves a non-thermal chemical process using a photosensitizing drug that can be given intravenously, orally or topically. The drug concentrates in the metaplastic and dysplastic epithelium and is sensitized by a bright light of appropriate wavelength to facilitate tissue necrosis. The main advantage of this technique is that larger areas can be uniformly treated with a single treatment session. PDT was found to be equally effective as APC in ablating Barrett's mucosa but more effective in eradicating dysplasia [8,11]. Oesophageal stricture and photosensitization are reported following the above techniques. Currently, there is insufficient evidence to support the use of these techniques in non-dysplastic IM.

Endoscopic resection techniques

Endoscopic mucosal resection (EMR) is an alternative technique to ablation in which the neoplastic epithelium is resected rather than ablated and hence gives a definitive histological diagnosis and potential cure. It can also be effectively used in the treatment of intramucosal cancer [12,13]. The EMR cap technique uses a transparent cap attached to the endoscope, which allows suction of the abnormal mucosa into the cap after submucosal injection of adrenaline. This can be resected using a snare and electrocoagulation [14]. Alternatively, oesophageal variceal ligation bands can be applied to the area of interest, followed by resection with a snare after removing the banding device. This is known as the 'suck-band-and-cut' technique [12]. No significant difference in the diameter of resected specimens, or in complications, was observed between these two techniques. Flat

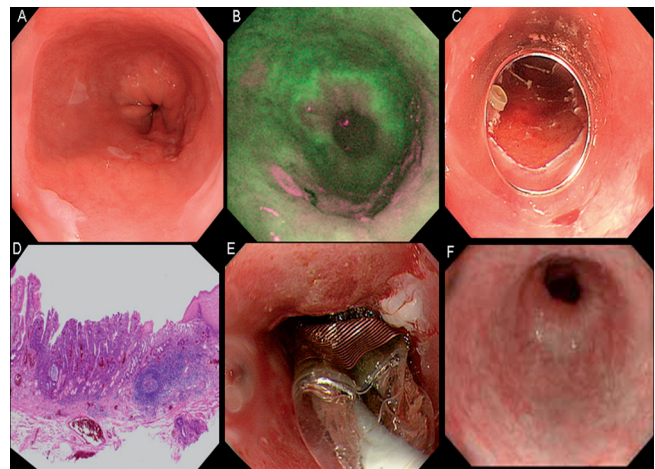
Barrett's neoplasia can also be removed using a monofilament polypectomy snare without the use of any submucosal lifting or additional devices [15]. Minor bleeding can occur in up to 10% of cases after EMR, but major complications such as perforation and strictures are rare.

Recent advances

En bloc dissection of large neoplastic lesions using a specially designed needle knife has been attempted by Japanese endoscopists, but this necessitates expertise. A multiband mucosectomy device (Duette; Cook Endoscopy, Winston-Salem, NC, USA, formerly Wilson-Cook Medical Inc), which allows resection of multiple areas using a technique like variceal banding ligation, is now commercially available. Unlike the suck-band-and-cut technique, it does not need a withdrawal of the scope between resections.

A newer technique of radiofrequency ablation (RFA) using a specially designed balloon known as the BARRX HALO system is available to ablate the neoplastic epithelium. Any visible abnormalities in the neoplastic mucosa are removed by EMR prior to RFA (Figure 1). HALO³⁶⁰ contains multiple electrodes encircling the outer surface of the balloon and can be used for circumferential ablation. Any residual Barrett's epithelium can be

Figure 1.



(a) High-resolution white-light image of Barrett's oesophagus with subtle irregular mucosa at the 5 o'clock position, (b) autofluorescence imaging revealing an abnormal signal between the 2 and the 7 o'clock positions, (c) multiband mucosectomy (Duette) endoscopic mucosal resection, (d) pathology showing intramucosal adenocarcinoma without submucosal invasion, (e) HALO³⁶⁰ radiofrequency ablation of remaining Barrett's epithelium, and (f) post-ablation squamous regeneration.

removed by focal ablation with the HALO⁹⁰ system. Initial reports suggest complete remission in dysplasia and Barrett's mucosa using this technique [16,17]. The incidence of residual dysplasia, oesophageal stenosis and buried Barrett's mucosa was reported to be less with RFA circumferential ablation compared with other ablative techniques.

Implications for clinical practice

Regular systematic surveillance of BO is warranted in the absence of any definitive measures available to prevent progression of disease. Endoscopic therapy for early neoplasia in BO is promising, but the ideal method is yet to be decided. EMR followed by RFA seems most promising. Patients with Barrett's neoplasia should ideally be treated in a dedicated centre with the help of a committed multidisciplinary team.

Abbreviations

APC, argon plasma coagulation; BO, Barrett's oesophagus; EMR, endoscopic mucosal resection; IM, intestinal metaplasia; PDT, photodynamic therapy; PPI, proton-pump inhibitor; RFA, radiofrequency ablation.

Competing interests

Dr Ragunath has received speaker honorarium, research support and educational grants from Astra-Zeneca UK, Cook Medical UK, Olympus-Keymed UK and BÂARX Medical Inc USA.

References

- Stein HJ, Siewert JR: **Barrett's esophagus: pathogenesis, epidemiology, functional abnormalities, malignant degeneration, and surgical management.** *Dysphagia* 1993, **8**:276-88
- Curvers WL, Singh R, Song LM, Wolfsen HC, Ragunath K, Wang K, Wallace MB, Fockens P, Bergman JJ: **Endoscopic tri-modal imaging for detection of early neoplasia in Barrett's oesophagus: a multi-centre feasibility study using high-resolution endoscopy, autofluorescence imaging and narrow band imaging incorporated in one endoscopy system.** *Gut* 2008, **57**:167-72
- Sampliner RE, Garewal HS, Fennerty MB, Aickin M: **Lack of impact of therapy on extent of Barrett's esophagus in 67 patients.** *Dig Dis Sci* 1990, **35**:93-6
- Sharma P, Morales TG, Bhattacharyya A, Garewal HS, Sampliner RE: **Squamous islands in Barrett's esophagus: what lies underneath?** *Am J Gastroenterol* 1998, **93**:332-5
- Abrams JA: **Chemoprevention of esophageal adenocarcinoma.** *Therapeutic Advances in Gastroenterology* 2008, **1**:7-18
- Heath EI, Canto MI, Piantadosi S, Montgomery E, Weinstein WM, Herman JG, Dannenberg AJ, Yang VW, Shar AO, Hawk E, Forastiere AA, Chemoprevention for Barrett's Esophagus Trial Research Group: **Secondary chemoprevention of Barrett's esophagus with celecoxib: results of a randomized trial.** *J Natl Cancer Inst* 2007, **99**:545-57
- Spechler SJ, Lee E, Ahnen D, Goyal RK, Hirano I, Ramirez F, Raufman JP, Sampliner R, Schnell T, Sontag S, Vlahcevic ZR, Young R, Williford W: **Long-term outcome of medical and surgical therapies for gastroesophageal reflux disease: follow-up of a randomized controlled trial.** *JAMA* 2001, **285**:2331-8
- Ragunath K, Krasner N, Raman VS, Haqqani MT, Phillips CJ, Cheung I: **Endoscopic ablation of dysplastic Barrett's oesophagus comparing argon plasma coagulation and photodynamic therapy: a randomized prospective trial assessing efficacy and cost-effectiveness.** *Scand J Gastroenterol* 2005, **40**:750-8
- Attwood SE, Lewis CJ, Caplin S, Hemming K, Armstrong G: **Argon beam plasma coagulation as therapy for high-grade dysplasia in Barrett's esophagus.** *Clin Gastroenterol Hepatol* 2003, **1**:258-63
- Sharma P, Wani S, Weston AP, Bansal A, Hall M, Mathur S, Prasad A, Sampliner RE: **A randomised controlled trial of ablation of Barrett's oesophagus with multipolar electrocoagulation versus argon plasma coagulation in combination with acid suppression: long term results.** *Gut* 2006, **55**:1233-9
- Overholt BF, Wang KK, Burdick JS, Lightdale CJ, Kimmey M, Nava HR, Sivak MV Jr., Nishioka N, Barr H, Marcon N, Pedrosa M, Bronner MP, Grace M, Depot M, International Photodynamic Group for High-Grade Dysplasia in Barrett's Esophagus: **Five-year efficacy and safety of photodynamic therapy with Photofrin in Barrett's high-grade dysplasia.** *Gastrointest Endosc* 2007, **66**:460-8
- Ell C, May A, Gossner L, Pech O, Günter E, Mayer G, Henrich R, Vieth M, Müller H, Seitz G, Stolte M: **Endoscopic mucosal resection of early cancer and high-grade dysplasia in Barrett's esophagus.** *Gastroenterology* 2000, **118**:670-7
- Nijhawan PK, Wang KK: **Endoscopic mucosal resection for lesions with endoscopic features suggestive of malignancy and high-grade dysplasia within Barrett's esophagus.** *Gastrointest Endosc* 2000, **52**:328-32
- Inoue H, Fukami N, Yoshida T, Kudo SE: **Endoscopic mucosal resection for esophageal and gastric cancers.** *J Gastroenterol Hepatol* 2002, **17**:382-8
- Soehendra N, Binmoeller KF, Bohnacker S, Seitz U, Brand B, Thonke F, Gurakuqi G: **Endoscopic snare mucosectomy in the esophagus without any additional equipment: a simple technique for resection of flat early cancer.** *Endoscopy* 1997, **29**:380-3
- Gondrie JJ, Pouw RE, Sondermeijer CM, Peters FP, Curvers WL, Rosmolen WVD, Ten Kate F, Fockens P, Bergman JJ: **Effective treatment of early Barrett's neoplasia with stepwise circumferential and focal ablation using the HALO system.** *Endoscopy* 2008, **40**:370-9

F1000 Factor 3.0 Recommended
Evaluated by Krish Ragunath 30 Jul 2008

- Pouw RE, Gondrie JJ, Sondermeijer CM, ten Kate FJ, van Gulik TM, Krishnadath KK, Fockens P, Weusten BL, Bergman JJ: **Eradication of Barrett esophagus with early neoplasia by radiofrequency ablation, with or without endoscopic resection.** *J Gastrointest Surg* 2008, **12**:1627-36 discussion 16367.